MSDPublications
Research is creating new knowledge

Research International Journal of Cancer Therapy and Radiology

Case Report

Received: 25 January, 2024
Accepted: 16 February, 2024
Published: 17 February, 2024

*Corresponding author: Mohammed Al Duhileb, Breast and Endocrine Oncology Surgeon, King Fahad Specialist Hospital-Dammam, Saudi Arabia; Tel: +966595909590, Email: duhailebm@hotmail.com

Copyright License: © 2024 Mohammed Al Duhileb, et al. This is an open-access article distributed under the terms of the Creative Commons Attribution License, which permits unrestricted use, distribution, and reproduction in any medium, provided the original author and source are credited.

Citation: Mohammed AID (2024) A Rare Presentation of Metastatic Breast Carcinoma to the Thyroid Three Years after Mastectomy: A Case Report. Rea Int J of Cancer Therapy and Radio. 2(1): 001-004. DOI: 10.37179/rijctr.000003

# A Rare Presentation of Metastatic Breast Carcinoma to the Thyroid Three Years after Mastectomy: A Case Report

**Mohammed Al Duhileb***

**Breast and Endocrine Oncology Surgeon, King Fahad Specialist Hospital-Dammam, Saudi Arabia.**

## Abstract

**Introduction:** Breast cancer is the most common cancer in women. Yet, metastasis to the thyroid is a rare occurrence. Here we present the case of a patient with breast cancer metastasis to the thyroid gland to discuss the management of such presentations compared to the current literature. We also present this case to add to the existing literature and aid in the expansion and better understanding of rare incidences as such.

**Presentation of Case:** A 38-year-old female with no chronic medical illnesses was diagnosed with invasive ductal carcinoma of the right breast T3N0M0 in 2017. Chemotherapy eight cycles of neoadjuvant chemotherapy followed by right simple mastectomy, sentinel lymph node biopsy, and adjuvant radiation to the chest wall. The patient has been on hormonal therapy since diagnosis. In 2020, the patient presented with a left neck mass and underwent a total thyroidectomy. Pathological analysis of the specimen confirmed the presence of poorly differentiated cells consistent with mammary ductal cells while the right thyroid lobe demonstrated features of papillary thyroid carcinoma.

**Conclusion:** Intrathyroidal metastasis of extrathyroidal cancers is rare but should be considered when patients are present with a history of cancer. Thyroidectomies in isolated secondary thyroid cancers have been shown to prolong the disease-free period but are not a definitive cure.

**Keywords:** Case Report, Breast Cancer, Metastases, Thyroid Cancer.

## Introduction

Breast cancer is the most common cancer in women. It frequently metastasizes to the lungs, bone, liver, and brain. Yet, metastasis to the thyroid is a rare occurrence with an incidence rate of 0.02-1.4% [1, 2]. As a result, the literature is scarce and there is no proven way on the best management plan. Here we present the case of a patient with breast cancer metastasis to the thyroid gland three years after the completion of her treatment of breast carcinoma followed by a discussion of the management of secondary thyroid cancer compared to the current literature.

### Presentation of Case

This is a case of a 38-year-old Saudi female who presented to the breast clinic with a right breast mass in 2017 for one year with no other symptoms and no risk factors for breast cancer. Her past medical and surgical history were not significant. Her medication history, psychosocial history, and family history were unremarkable. On

clinical examination, there was a palpable right upper quadrant breast mass 6x5cm in size, irregular with no associated features of invasive carcinoma and no palpable axillary lymph nodes. Ultrasound of the breast bilaterally was done which showed multicentric lesions in the right breast, BIRADS 6.

The left breast was unremarkable. Staging with CT-CAP and PET scan confirmed the absence of metastasis, T3N0M0. Core needle biopsy (Figure 1) was consistent with invasive ductal carcinoma grade 2 and was ER+, PR+, Her2-Neu equivocal, and Ki-67 index= 40%. The tumor board consensus was for neoadjuvant chemoradiation (four cycles of Adriamycin and cyclophosphamide, four cycles of Taxotere) followed by simple mastectomy with sentinel lymph node biopsy. Four reactive lymph nodes were negative for malignancy. Subsequently, the patient received adjuvant radiation to the right chest wall, supraclavicular, and axilla 50GY/25F. As well as tamoxifen which she currently is still on.

The patient was referred to our endocrine surgery clinic in September 2020 complaining of a painless neck lump for 9 months, gradually increasing in size and associated with intermittent odynophagia and sleep apnoea. The patient denied any history of hoarseness, dysphagia, and dyspnoea. She did, however, report weight gain, fatigability, and cold intolerance. There was an unclear positive family history (mother and sisters) for thyroid lesions that necessitated a total thyroidectomy. The only confirmed risk factor is her exposure to external beam radiation of the chest and axilla. On clinical examination, there was a firm, non-tender left thyroid lump, 5x3cm in size with smooth, regular borders. There was no retrosternal extension and no palpable cervical lymph nodes with a central trachea. Thyroid function tests revealed a TSH of 3.27, FT3 of 4.01, and FT4 of 12.61. A complete blood count showed a white blood cell count of 1.66 X10^9/L and hemoglobin of 13.8 g/dL.

A thyroid ultrasound (Figure 2) was performed which showed an enlarged left thyroid lobe with a hypoechoic solid thyroid nodule 5.2 cm in size with microcalcifications corresponding to TR5. Fine needle aspiration of the nodule was positive for malignant cells.

After a multidisciplinary discussion, a decision to proceed with a total thyroidectomy was made. The patient was admitted to the hospital, consented, underwent a smooth procedure under general anesthesia, was in a supine position with no intraoperative complications, and was discharged home in stable condition. The final histopathology (Figure 3) of the right thyroid lobe showed papillary thyroid carcinoma, conventional type, 1.2cm in size, pT1b, pNx. The left thyroid lobe showed metastatic poorly differentiated carcinoma, 7cm in size, consistent with mammary ductal origin. The patient was seen in our clinic one week after discharge for wound evaluation and histopathology results. She is now being followed up with endocrinology to manage her thyroid medication.

## Discussion

Breast cancer incidence Brest cancer stage by stage incidence Breast cancer metastasis, most common places % breast cancer Mets to the thyroid, Malignant cells have the propensity to spread to highly vascularized organs but despite the thyroid having an affluent blood supply per weight of tissue (560 mL/100 g tissue/min), it is rarely the site for metastasis [3]. Renal cell carcinoma is the most common primary tumor accounting for 79% of metastatic disease to the thyroid, while primary breast cancer equates to as little as 3% [4]. Therefore, it is difficult to establish an accurate rate of breast cancer metastasizing to the thyroid. However, studies have claimed that pre-existent thyroid pathologies such as goiter and hypothyroidism increase the rate of metastatic disease to the thyroid [3, 5]. This could be explained by the changes that occur to thyroid homeostasis resulting in decreased oxygen and increased iodine content. In contrast to the aforementioned case which highlighted a medically free patient. This suggests that concurrent thyroid pathology does negate the possibility of secondary thyroid cancer in healthy individuals.

Metastatic disease of the thyroid, albeit still rare, is at a steady increase over time with neck mass being the most common presentation (71%) [2, 6]. One can hypothesize that this is due to the constant improvements in fine-needle aspirate (FNA) techniques which in turn reduces the chances of

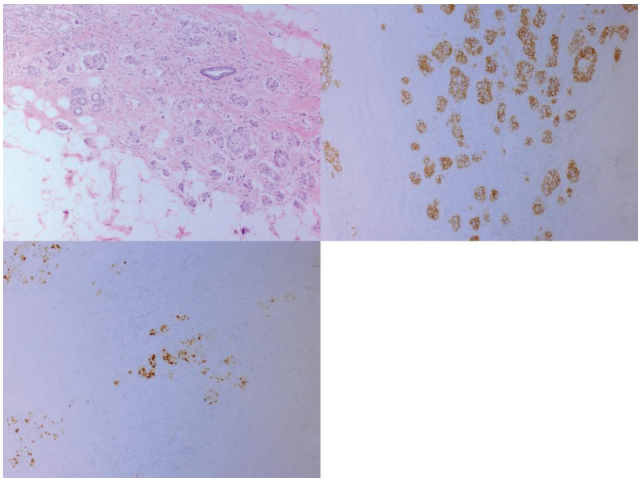

**Figure 1:** (A) Right breast tissue showing solid nests of invasive ductal carcinoma cells.
(B) Invasive ductal carcinoma cells are positive for E-cadherin immunostaining.
(C) Invasive ductal carcinoma cells are positive for Oestrogen Receptor immunostaining.

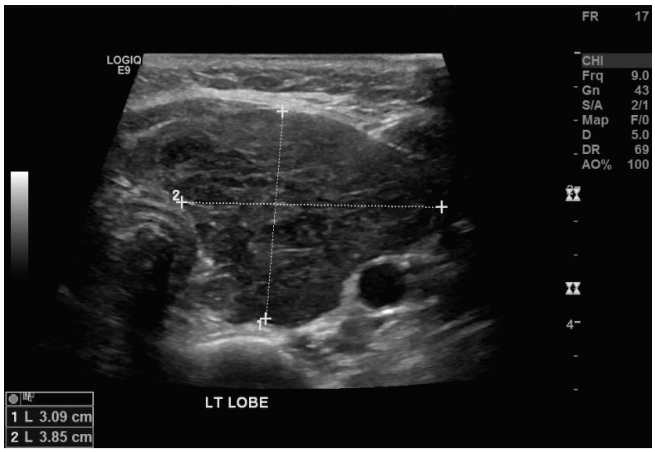


**Figure 2:** The left thyroid lobe is enlarged showing a well-circumscribed hypoechoic solid nodule with microcalcification measuring 5.2 cm.

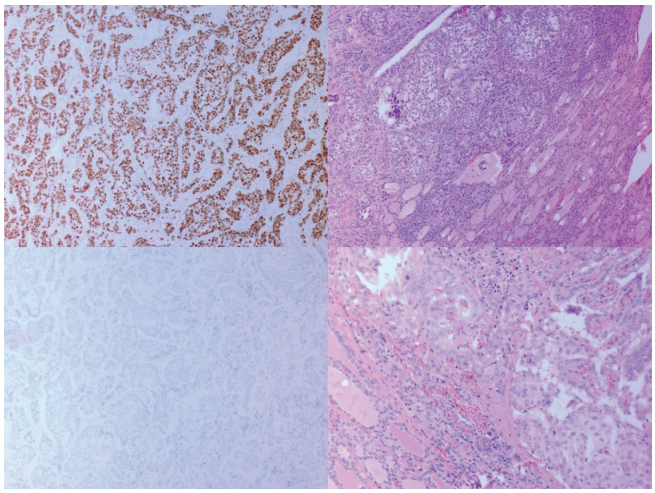

**Figure 3:** (A) Metastatic mammary ductal carcinoma to the thyroid gland is positive for GATA3 immunostaining, confirming the mammary origin.
(B) Metastatic mammary ductal carcinoma to the thyroid gland.
(C) Metastatic mammary ductal carcinoma to the thyroid gland is negative for Thyroid Transcription Factor-1 (TTF1) immunostaining.
(D) Papillary Thyroid carcinoma cells with nuclear clearing, overlapping, and squamous areas.

obtaining a false negative result, making it a more sensitive test. The increase in sensitivity results in an increase in the accuracy of FNA in diagnosing secondary thyroid (90%) [7], this could be attributed to the experience obtained by the technician in ultrasound-guided FNA. On the other hand, the FNA done on our patient only confirmed the presence of malignant cells. Thus, suspicion of secondary thyroid cancer should arise when abnormal characteristics of primary thyroid cancer are present, or if the patient presents with a history of malignancy (renal cell carcinoma, oesophageal carcinoma, breast carcinoma).

There is no clear consensus on the role of surgery in the treatment of isolated metastatic disease to the thyroid. Despite surgery being an uncommon route for the management of metastatic disease to the thyroid, it has proven to be beneficial in palliative measures as it extends the disease-free period [6, 8]. Surgical intervention can be considered in cases of a solitary thyroid nodule, small size, or if the patient is symptomatic, as was the case with our patient. Numerous studies were conducted on the role surgery plays in the treatment of such cases, although non-statistically significant, have demonstrated a longer survival rate in patients treated with thyroidectomy compared to those managed conservatively [9-12]. On the other hand, a study conducted by Nixon IJ et al claims that there is no proven advantage of surgery in the management of secondary thyroid cancer aside from obtaining a confirmed pathological diagnosis and avoiding local aggressive central neck disease [2]. All the reported studies were based on a small cohort, due to the rarity of the disease. Therefore, operative decisions for cases like the one described above are based on retrospective studies and case reports.

Metastatic thyroid carcinoma is associated with a poor outcome as it reflects the aggression and advanced stage of the primary cancer [8]. The mean survival is three years post-diagnosis of metastasis to the thyroid and six years from the diagnosis of primary cancer as reported by a Mayo Clinic Series [8]. Another study reported the median survival from the time of surgery to the time of death or last follow-up was 24 months (range 2-114 months) [2]. These numbers will be difficult to mirror in our patient presented above as it remains a recent case since her diagnosis of secondary thyroid carcinoma. Our patient will require regular follow-up visits to ensure a better quality of life that is disease-free.

## Conclusion

Intrathyroidal metastasis of extrathyroidal cancers is rare but should be considered when patients present with a history of cancer. Proper preoperative evaluation of the patient including a thorough clinical, radiological, and pathological exam must be conducted to exclude further metastases which allows the surgeon to map out the optimal management plan best suited for the patient in question. Thyroidectomies in isolated secondary thyroid cancers have been shown to prolong the disease-free period but are not a definitive cure. Further studies need to be conducted to establish proper management guidelines.

**Consent:** Written informed consent was obtained from the patient for publication of this report and any accompanying images.

**Conflict of interest**: The authors declare that they have no conflict of interest.

**Scare checklist statement:** The authors have read the SCARE guidelines (2018), and the manuscript was prepared and revised according to the SCARE guidelines (2018).

## References


1. Irvin W, Muss HB, Mayer DK (2011) Symptom management in metastatic breast cancer. Oncologist 16:1203-1214. Link: https://bit.ly/4bGA0mc

2. Nixon IJ, Whitcher M, Glick J, Palmer FL, Shaha AR, et al. (2011) Surgical management of metastases to the thyroid gland. Ann Surg Oncol 18: 800-804. Link: https://bit.ly/3OOE22b

3. Zhou L, Chen L, Xu D, Shao Q, Guo Z, et al. (2017) Breast cancer metastasis to thyroid: a retrospective analysis. Afr Health Sci 17: 1035-1043. Link: https://bit.ly/3wkC97a

4. Surov A, Machens A, Holzhausen HJ, Spielmann RP, Dralle H (2016) Radiological features of metastases to the thyroid. Acta Radiol 57 :444-450. Link: https://bit.ly/49dwnCF

5. Chung AY, Tran TB, Brumund KT, Weisman RA, Bouvet M (2012) Metastases to the thyroid: a review of the literature from the last decade. Thyroid 22: 258-268. Link: https://bit.ly/3UAhdmG

6. Hegerova L, Griebeler ML, Reynolds JP, Henry MR, Gharib H (2015) Metastasis to the thyroid gland: report of a large series from the Mayo Clinic. Am J Clin Oncol 38: 338-342. Link: https://bit.ly/48iU6QN

7. Aron M, Kapila K, Verma K (2006) Role of fine-needle aspiration cytology in the diagnosis of secondary tumors of the thyroid--twenty years' experience. Diagn Cytopathol 34: 240-245. Link: https://bit.ly/3OJrlWw

8. Mirallié E, Rigaud J, Mathonnet M, Gibelin H, Regenet N, et al. (2005) Management and prognosis of metastases to the thyroid gland. J Am Coll Surg 200: 203-207. Link: https://bit.ly/3UHB1ob

9. McCabe DP, Farrar WB, Petkov TM, Finkelmeier W, O'Dwyer P, et al. (1985) Clinical and pathologic correlations in disease metastatic to the thyroid gland. Am J Surg 150: 519-523. Link: https://bit.ly/42JCBYO

10. Calzolari F, Sartori PV, Talarico C, Parmeggiani D, Beretta E, et al. (2008) Surgical treatment of intrathyroid metastases: preliminary results of a multicentric study. Anticancer Res 28: 2885-2888. Link: https://bit.ly/3SJoL3Z

11. Cichoń S, Anielski R, Konturek A, Barczyński M, Cichoń W (2006) Metastases to the thyroid gland: seventeen cases operated on in a single clinical center. Langenbecks Arch Surg 391: 581-587. Link: https://bit.ly/3HZrUrd

12. Papi G, Fadda G, Corsello SM, Corrado S, Rossi ED, et al. (2007) Metastases to the thyroid gland: prevalence, clinicopathological aspects and prognosis: a 10-year experience. Clin Endocrinol (Oxf) 66: 565-571. Link: https://bit.ly/3OLhBeb