

Review Article

Unraveling the mystique of left main stenting: A bugaboo of coronary intervention

Rohit Mody^{1*}, Debabrata Dash², Bhavya Mody³, Anand Reddy Maligireddy⁴, Ankit Agrawal⁵, Lakshay Rastogi⁶

¹Department of Cardiology, MAX Super specialty hospital, Bathinda, Punjab, India.

ORCID - <https://orcid.org/0000-0001-8977-5803>

²Department of Cardiology, Aster Hospital, Dubai, Al Quasis, UAE.

ORCID- <https://orcid.org/0000-0003-1354-3808>

³Department of Medicine, Kasturba medical college, Manipal, Karnataka, India.

ORCID- <https://orcid.org/0000-0001-8944-9418>

⁴Department of Cardiology, Mayo Clinic, 13400 E Shea Blvd, Scottsdale, AZ 85259, USA.

Drmaligireddy@gmail.com

ORCID- <https://orcid.org/0000-0003-3608-4923>

⁵Department of Cardiology, Cleveland Clinic, 9500 Euclid Avenue Cleveland, Ohio 44195,

drankit.agrawal@gmail.com USA

ORCID- <https://orcid.org/0000-0001-7885-6667>

⁶Department of Cardiology, Kasturba Medical College, Manipal, India. Dr.lakshay.rastogi@gmail.com

ORCID - <https://orcid.org/0000-0002-7746-5389>

Received: 28 May, 2022

Accepted: 07 July, 2022

Published: 11 July, 2022

***Corresponding author:** Rohit Mody, Department of Cardiology, MAX Super specialty hospital, Bathinda, Punjab, India. Tel: +91-9888925988; E mail: drmody_2k@yahoo.com

Keywords: Left main coronary artery, percutaneous coronary interventions, bifurcation lesions, drug-eluting stent.

Copyright: © 2021 Rohit M, et al. This is an open access article distributed under the Creative Commons Attribution License, which permits unrestricted use, distribution, and reproduction in any medium, provided the original work is properly cited.

Abstract

For many years, CABG has been the gold standard treatment for unprotected Left Main (LM) coronary artery lesions. Because of its high artery size and anatomical accessibility, the LM lesion makes a good PCI candidate. Subset PCI has been broadened by the development of Drug-Eluting Stent (DES) as well as fast advances in procedures, devices, and adjunct pharmacotherapies. PCI and CABG had equivalent results in patients with low or moderate coronary complexity for up to five years, according to current research. Most LM bifurcation lesions may be treated successfully with a single provisional stent rather than the more complex two-stent treatment. The unusual instance of a bifurcation lesion, which requires the use of not one, but two stents from the start, is an exception to the norm. Controlling this unusual species and improving treatment outcomes need an integrated strategy involving specialized procedures, additional physiological and morphologic assessment, and hemodynamic devices.

Introduction

It is estimated that 5–7 percent of individuals who undergo CAG have significant unprotected (LMCAD), with more than 80 percent of these patients suffering from bifurcation [1-3]. When it comes to revascularization, coronary artery bypass surgery (CABG) is still the best option for people with unprotected coronary artery disease [4-5]. Left Main (LM) is a common candidate for percutaneous coronary intervention (PCI) because of its anatomic accessibility and relatively big artery size [6]. Interventional cardiologists have been inspired to pursue PCI because of major technological advancements in PCI, as well as more recent drug-eluting stents (DESs) [7]. Although PCI has a greater occurrence of recurrent revascularization than CABG, there is no difference in the overall incidence of major adverse cardiovascular events between the two procedures, according to randomised clinical trials (RCTs). When

tried to compare to LM bifurcations, [8-12] PCI of the ostial and mid-shaft has shown good results with lower mortality and long-term complications [10]. LM bifurcation has not been studied in RCTs; hence the best stenting method is unknown. Two-stent procedures are more prevalent than temporary one-stent treatments for complicated LM bifurcation lesions [13].

Anatomy and rheology

Due to its large calibre, the LM has a huge plaque volume. It also is prone to calcification. Plaque and carina shift, as well as partial stent expansion, must be considered while doing LM PCI. The elastic recoil and significant restenosis observed during balloon angioplasty are likely due to the artery's higher elastic tissue composition [14, 15]. The main motivation of LM PCI approaches is side branch (SB) difficulties, including acute occlusion and long-term adverse consequences of target

vessel failure (TVF) and target lesion revascularization (TLR). Low wall shear stress (WSS) is a factor in the progression of atherosclerosis in the LM bifurcation area of the lateral wall of the left anterior descending artery (LAD) [16]. Most of the time, the carina is left out of the image. Each of these three factors interacts with the other. Atherogenesis and thrombosis are both influenced by local hemodynamic variables. A long LM (>10 mm) has a lower WSS, and a larger pressure drop, both of which contribute to plaque development [17]. Computational fluid dynamics models show how atherosclerotic plaque forms at bifurcation points with low WSS, fluctuating flow and stasis [18].

A higher average WSS makes the Medina 1.1.0, 1.1.1, and 1.0.1 bifurcations more resistant to atherogenesis than Medina 1.0.0, which has the highest risk of plaque proliferation. 18 When it comes to the treatment of LM bifurcation in 90% of instances, the current technique is backed by the continual extension of plaque to the proximal LAD artery through the main branch (MB) stent [19]. The LAD and Left Circumflex (LCX) have diameters of 3.0–4.5 mm and 3.0–4.5 mm, respectively, while the LM has a diameter of 4.5–6 mm. Interventional cardiologists need to get acquainted with big diameter stents that really can expand [20].

There is a correlation between higher bifurcation angles (between LAD and LCX) and the outcome of culotte and classic crush techniques [21-23]. When the bifurcation angle between the LAD and the LCX is less than 70°, culotte stenting has a reduced risk of MACE. When the

bifurcation angle between the LAD and the LCX is greater than 70°, double kissing (DK) crush has a lower rate of MACE [24]. DK crush may be the most successful two-stent approach to date when the LCX is less than the LAD or the bifurcation angle is greater (but larger than 2mm). It is possible to apply the culotte or DK crush approach if the bifurcation angle is less than 70° and LCX is equal to or within 0.5mm of the diameter of the LAD [16-25]. If you have diffuse LM, you may not detect stenosis. The illness is diffuse if the LM's reference diameter is the same as the LAD's.

Why is LM stenting a different animal?

When it comes to coronary tree bifurcations, the LM is the most complex and requires a different approach than other coronary bifurcations.

- A. More than half of the total mass of the heart is made up of the myocardium derived from the left ventricle. An error in technique might result in a catastrophic outcome because of the larger myocardium that is at risk. In the long run, the outcome might be altered.
- B. When it comes to strategic and technological consequences, there is no other bifurcation where the proximal MB originates from the aorta. In contrast to other portions of the coronary tree, LM's ostium resists the radial force supplied by the stent substantially better than other aortic components. Stent recoil has been documented, needing a further implant inside an already existing one.
- C. The proximal reference diameter of this sort of bifurcation is typically between 4.5 and 6 mm, which is rather big when compared to the present DES size.
- D. It is possible for diffuse LM disease to seem disease-free, however, this is not always the case [26]. If the LM's reference diameter is equal to the LAD's, the branching law principles can be used to identify diffuse LM disease.

- E. 10% of LM cases reveal trifurcations that necessitate concrete treatment strategies [27].
- F. Like any other non-LM bifurcation, the atheroma of an LM bifurcation is seen in places that are not directly next to the flow divider. However, the distribution of LM bifurcation is more spread out [18]. Long-term prognosis, on the other hand, maybe influenced by the location of plaques [28].
- G. Calcification is prevalent in LM lesions [29]. Atherectomy and other methods of plaque remodeling are now more essential than before. Because of the T-shape of the bifurcation angle in LM, stenting may have an adverse effect on prognosis [30]. Stent fracture and long-term unfavorable clinical outcomes can result from a reduced systolic-diastolic fluctuation of the bifurcation if the angle is broader [31]. Wide bifurcation angles have been observed to have areas of high shear stress close to areas of low shear stress, which may stimulate platelet activation and aggregation and result in a localized milieu of stasis and thrombosis, respectively [32, 33]. Stent insertion in bifurcations with >70° angles generates considerable rheological changes and may result in unsatisfactory stent attachment, particularly when utilising a two-stent approach [34, 35].
- H. Many studies have shown that inadequate revascularization raises the risk of MACE. A SYNTAX (Synergy between PCI with Taxus and Cardiac Surgery) score of more than 8 carries substantial risk [36]. When it comes to patients who have LM disease, persistent blockage of the right coronary artery is linked to an increased mortality risk if left untreated [37, 38].
- I. Major issues may be large territory, large vessel size, incompatible of atherectomy device, wide angle of LCX, importance of LCX as SB and motion of LCX ostium. The primary goal of treatment is to improve life expectancy, not symptom.

What the trials and major guidelines have to say?

Few large RCTs trying to compare the outcomes of CABG and PCI for LM lesions. In 2018, European guidelines supported PCI as an alternative to CABG in LM disease with low-to-intermediate anatomic complexity, based on recent randomised controlled studies (class I recommendation for low SYNTAX scores and class IIa for intermediate SYNTAX scores; the recommendation was against PCI [class III] for high SYNTAX scores) [39]. Due to concerns regarding the EXCEL (Evaluation of XIENCE Everolimus-Eluting Stent Versus Coronary Artery Bypass Surgery for Efficacy of Left Main Revascularization) study, surgical associations recently withdrew their endorsement for this recommendation [40].

In the EXCEL research, 1,905 patients were randomly assigned to have PCI with DES (using Abbott's Xience everolimus-eluting stent technology) or coronary artery bypass graft (CABG). At five years, 22 percent of PCI patients and 19.2 percent of CABG patients experienced the composite primary outcome of cause mortality, stroke, or MI [41]. Following PCI, there was a substantial increase in overall mortality. In terms of cardiac death or MI, there were no statistically significant differences between the two groups.

There was a significantly higher rate of major adverse cardiac and cerebrovascular events (MACCE) in the PCI group compared with the CABG group in the NOBLE trial, which examined the effectiveness of percutaneous coronary angioplasty (PCI) with a biolimus-eluting stent

(Biomatrix Flex, Biosensors) in treating unprotected left main stenosis. All-cause mortality and cardiac death rates were the same in both groups [42]. Despite using the now-defunct paclitaxel-eluting Taxus stent device, the SYNTAX study [43] showed no difference in 10-year all-cause mortality in the PCI group (Boston Scientific Corporation, USA).

To evaluate the long-term effects of any therapy and better guide decision-making, a minimum of five years of follow-up is required [44]. The EXCEL 5-year data show an initial stage in which CABG causes more events (up to 30 days), an interval period (up to 12 months) in which events are equivalent between arms, and a later period (between 12 months and 5 years) in which the PCI arm experiences more events than the CABG arm. According to the NOBLE study, more people died after a year of treatment in the CABG arm than the PCI arm. Comparing PCI to CABG over the long run, the results demonstrate a catch-up tendency.

A cardiac team strategy was used in all studies comparing PCI and CABG in the LM disease domain, and revascularization could be performed with either method. As a result, all therapeutic decisions should be made with the cardiac team in consideration. Patients must be well-informed and comforted that there are now two safe, effective options available to them.

How to plan for LM intervention?

To ensure the best results, the LM PCI should only be conducted by skilled interventional cardiologists who are well-versed in stenting procedures, coronary physiology, mechanical circulatory support, and atherectomy at facilities equipped with intracoronary imaging (IVUS or OCT). If an LM lesion is not properly delineated by Coronary Angiography (CAG), further imaging or functional testing may be required. However, the Medina Classification [45, 46] of bifurcation lesions outlines plaque distribution and procedure planning but does not predict PCI outcome. It is possible that two-stent procedures may be necessary for patients with large SBs, a long SB lesion, a wide bifurcation angle, and an increased risk of hemodynamic deterioration owing to probable SB occlusion.

Anatomically specific quantitative coronary angiographic software is required for this classification's validity. To do an LM intervention, the following requirements must be met: 70% LM diameter stenosis by CAG, a minimum lumen area (MLA) of 6.0mm² by IVUS or OCT, and a Fractional Flow Reserve (FFR) of 0.80 [13].

IVUS and OCT

Because of the vessel overlap, angulation and deformity, foreshortening and streaming of contrast, the LM segment is difficult to analyze by CAG. The LM and daughter vessel diameters, plaque distribution, tissue features, a calcification arc, and the degree of stenosis, as well as devising a treatment plan and optimizing the result, all need IVUS or OCT imaging. PCI can be postponed until an IVUS-derived cutoff value of 6mm² (threshold) has been shown to be safe [47]. An IVUS MLA of <4.5mm² in the Asian population, on the other hand, correlates to an FFR of <0.8 [48].

Compared to IVUS, OCT delivers a more accurate picture of the lumen and intima because of its better resolution. When compared to IVUS, OCT has drawbacks such as a smaller perforation depth and difficulties flushing the LM lumen. Injecting 20 mL of contrast at a pressure of 500 psi for five seconds improves image quality. IVUS and OCT findings indicating pre-procedure "spiky" or "eyebrow" carina or "spike" near the origin of the SB, which predicts carina shift and restenosis following LM PCI, are comparable with these findings [49]. Relative merits of IVUS vs OCT in LM PCI are depicted in (Figure 1 & 2) and (Table 1).

FFR

There has been no defined agreement on the exact FFR cut off point

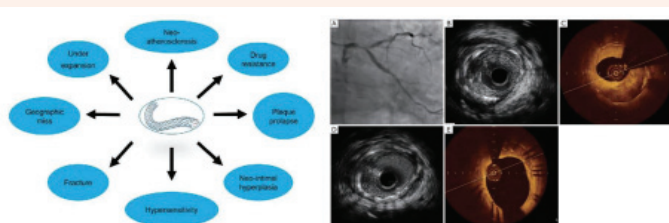


Figure 1: Relative merits of IVUS vs OCT in LM PCI. Imaging in ISR

- > Figure 1a. Technical & Biological Mechanisms of ISR
 - > Figure 1b. ISR patterns as evaluated by IVUS and OCT
- † ISR = In-stent Restenosis; IVUS = Intravascular Ultrasound; OCT = Optical Coherence Tomography

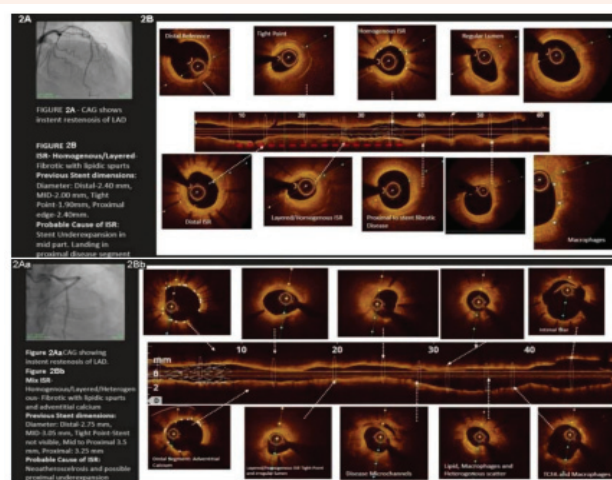


Figure 2: OCT patterns of ISR in different situations.

- Relative merits of IVUS vs OCT in LM PCI
- LM Bifurcation comparison between OCT & IVUS Images-
- A. OCT more clearly shows Bifurcation
 - B. Calcium More clearly delineated by OCT than IVUS
 - C. Ostium More clearly delineated by IVUS
- Stent Optimization more studied with IVUS than OCT
- †OCT = Optical Coherence Tomography; ISR = In-stent Restenosis

Table 1: Analysing CAG, IVUS and OCT in different PCI situations.

Clinical feature	Angiography	IVUS	OCT
Appraisal of LMCA stenosis	+	+++	+
Appraisal of non-LMCA stenosis	++	++	+++
Localize the culprit lesion	+	++	+++
Identify a vulnerable plaque	0	++ (VH-IVUS)	+++
Clinch the possibility of MI during procedure and risk of distal embolization	0	+++ (VH-IVUS)	++
Size the vessel undergoing stent implantation	++	+++	+++
Optimize stent results	+	+++	+++
Evaluate stent thrombosis or restenosis	+	++	+++

0 = no data; + = less data; ++ = moderate data; +++ = extensive data.
 †CAG = Coronary Artery Angiography; IVUS = Intravascular Ultrasound; LMCA = Left Main Coronary Artery; MI = Myocardial Infarction.

for LM PCI. LM PCI may be postponed in individuals with an FFR greater than 0.85. Revascularization is considered when the FFR is 0.80. If an FFR value falls between the range of 0.80 to 0.85, an IVUS examination should be performed. When administering intravenous adenosine, the guide catheter must be removed from the ostium to avoid the artefact of guide catheter pressure damping. There are two FFR measures that may be used to evaluate a bifurcation LM stenosis in the LAD and LCX: the LAD measurement and the LCX test utilising a pressure wire.

It can be difficult to interpret the LM FFR even when there are significant downstream branch lesions, such as LAD stenosis. This is because the LM and LAD lesions are sequential, and severe downstream stenosis can reduce genuine flow over the LM, artificially increasing the LM FFR when measured in the unobstructed channel. True LM FFR can be measured after PCI of the downstream lesions has been performed. Following LM-LAD crossover stenting [50], FFR guiding may lessen the requirement for PCI of the ostial LCX [51]. For provisional SB stenting, either the CAG or FFR-guided method may be suggested based on their similar 1-year MACE rates in the DKCRUSH-VI study [52]. The efficacy of this technique will have to be confirmed in subsequent RCTs, however.

LM ostial and mid-shaft stenting

With a single stent method, these lesions can be successfully treated, both short- and long-term. Direct stent placement in the midshaft is a possibility, but the diameter of the conduit, the length of the lesion, and the degree of calcification should all be considered before proceeding. The possibility of plaque shift should be regarded. The stent can be placed in the LAD across the LCX ostium if the LM shaft is too short. Intracoronary imaging is required to obtain clear images of the ostium and the surrounding aorta. An anteroposterior (AP) or left anterior oblique (LAO) cranial projection provides the finest vision whether seen from the front or back. The guiding catheter might become occluded if the lesion is serious enough. The wire should be gently pushed against the ostium to reduce cardiac ischemia. Using wire traction, the guide can then be gradually pushed toward the ostium to facilitate injection and imaging. The use of Amplatz guides should be avoided in ostial lesions, however, short-tipped guides are suitable in these cases as well. The stent should be implanted with 1–2 mm of protrusion into the aorta after appropriate pre dilatation. This is necessary to guarantee appropriate stent attachment at the ostium's entrance. Improved outcomes may be achieved with the use of intravascular imaging [13].

Crafting a strategy in LM bifurcation

For 75 percent of LM bifurcation lesions, the “provisional method” (implantation of one DES in the MB and subsequent balloon dilation/DES implantation within the SB only if necessary) is considered as the gold standard. But for complicated bifurcated lesions with severe SB disease, the use of the two-stent method is advised. When comparing the two-stent technique to the one-stent strategy, the DEFINITION (Definitions and Impact of Complex Bifurcation Lesions on Clinical Outcomes After Percutaneous Coronary Intervention Using Drug-Eluting Stents study) trial found that the two-stent technique is associated with better clinical outcomes for complex LM bifurcation lesions [53]. As shown in the DKCRUSH-V study, the DK crush approach had a lower three-year TLF and ST rate than provisional stenting [54].

A For LM bifurcation, the EBC MAIN (European Bifurcation Club Left Main) study concludes that an initial two-stent technique is not inferior to the temporary layering approach [55]. At 1 year, the researchers found no

significant differences in the primary endpoint's constituent components or the primary endpoint itself between the two techniques. Rather than “prejudicing” the circumstance by opting for a more complicated two-stent procedure right away, this research suggests pursuing a sequential, layered provisional approach and starting with just one stent. Larger RCTs are needed to verify this, though. The goal of this study was not to see how well one stent performed compared to two. When compared to the two-stent method with a culotte and T/T and protrusion (TAP) in more than two-thirds of patients, a preliminary approach that included at least one-fifth of patients had neutral results.

There are several factors that go into deciding on a treatment plan (plaque distribution, the diameter of the daughter branches, the angle between them and anatomy of the SB). It is common to practice using a single provisional stent, with the option of adding a second stent in the form of a T, TAP, or culotte if necessary. If the lesion is more complicated, an initial two-stent technique might be required (Figure 3). DEFINITION criteria are used to classify the LM bifurcation as simple or complicated to assist select the appropriate stenting method [53]. If the SB diameter stenosis is less than 70% and the lesion length is less than 10 mm, which is seen in 75% of cases, it is referred to as simple stenosis.

A complex LM bifurcation lesion has stenosis of the SB diameter of more than 70% and a lesion length greater than 10 mm. A simple lesion could become complex if two of the six minor criteria listed below are present. 1): Moderate-to-severe calcification 2): Multiple lesions 3): LAD-LCX bifurcation angle >70 4): MB reference vessel diameter >2.5 mm 5): Thrombus-containing lesions and 6): main branch lesion length >25 millimeters. An interventionist's skill and the size, bifurcation angle, severity and duration of the primary SB lesion have a role in the decision to utilize a certain sort of complicated two-stent technique. The DK crush approach can be applied effectively in practically all forms of complicated LM bifurcation, even if there is no consensus and limited data on the ideal two-stent technique [56].

Provisional one-stent technique

Provisional stenting with a single stent crossing into either the LAD or the MB is the conventional approach in LM bifurcation lesions. If the LM has a small (50 percent) ostial LCX or if the SB lesion is 10 millimeters in

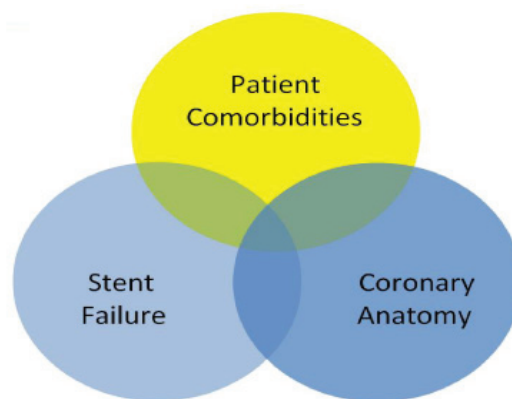


Figure 3: Percutaneous coronary intervention at the left main bifurcation algorithm.

which patient's benefits from imaging guidance?

Abbreviations: LM, left main; SB, side branch; TAP, T and protrusion; DK crush, double kissing crush; FFR, fractional flow reserve; TIMI, thrombolysis in ; IVUS, intravascular ultrasound; OCT, optical coherence tomography.

length, if the coronary artery system is not left dominant, or if the LCX is 2 millimeters in diameter, a single stent method is preferable. An inverted provisional approach (provisional one stent from LM to LCX) should be used if the major lesion is in the LCX (behaving as MB) and there is no ostial illness of the LAD. After resizing with a distal MB as a guide, a stent is inserted from the LM to the LAD in the provisional method. At least six or eight millimeters in length, a short, larger-diameter balloon should be inserted into the stent, which should be positioned near enough to the SB to allow for the entrance of the balloon. To apply the proximal optimization technique (POT) [46], a balloon diameter of 1:1 is used from the proximal MB calibre up to the carina level (Figure 4).

To facilitate seamless guidewire replacement, this allows for bigger strut apertures and strut protrusion into the SB, coupled with no or restricted carina shifting. At the carina, the balloon's distal shoulder should be precisely aligned. In cases of stent under expansion, the non-compliant balloon is favored over the semi-compliant alternative. There are now three SB alternatives available. 1) POT is performed after crossover stenting but before SB dilatation or kissing balloon inflation (KBI) has taken place. 2) It is possible to remove and re-introduce the LAD guidewire to allow strut projection in the SB's ostial segment opposite the carina, if required, by re-inserting the LAD guidewire. The LCX's "jailbroken" guidewire is detached and advanced to the LAD, where it is reconnected. As an alternative, you may gently pull back while rotating your wire tip downward into the LCX, crossing it over and entering it through your LAD using a slight double curve on your fresh wire tip. Following that, POT, KBI, and a re-POT will be conducted (Figure 5-9). For the POT, SB inflation, and re-POT without KBI, clinical testing is essential (Figure 10) [57].

To minimize LM dissection and oval distortion, KBI uses small, non-compliant balloons with limited overlap [58]. Murray's law is utilized to choose balloon sizes, and the balloon is inflated first in the SB, then deflated simultaneously. Proximal deformation can be minimized by employing an "asymmetric KBI technique" that inflates the SB to 12 atm, then deflates it to 4 atm, while simultaneously inflating the MB balloon at the same pressure [59].

Routine when used in combination with different techniques, such as provisional stenting that is later converted to a two-stent technique, KBI does not demonstrate a clear advantage. A greater MACE rate was seen in the COBIS (Korean Coronary Bifurcation Stenting) registry [60], in such patients, it was discovered in the DKCRUSH-II study's five-year follow-up that the provisional KBI group had an elevated TLR [61].

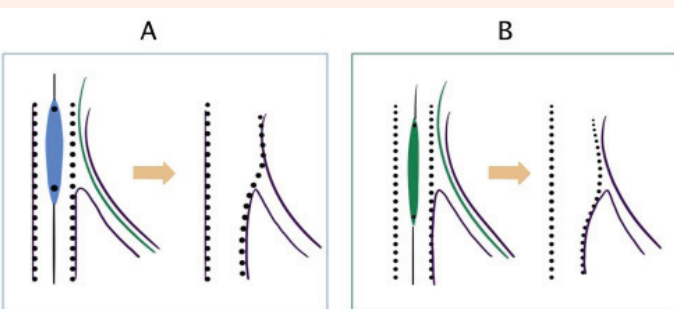


Figure 4: Illustration of balloon positioning in proximal optimization technique.

- A. Correct position is distal marker at the carina level.
- B. Distal marker distal to the carina causes malapposition at proximal segment and carina shift.

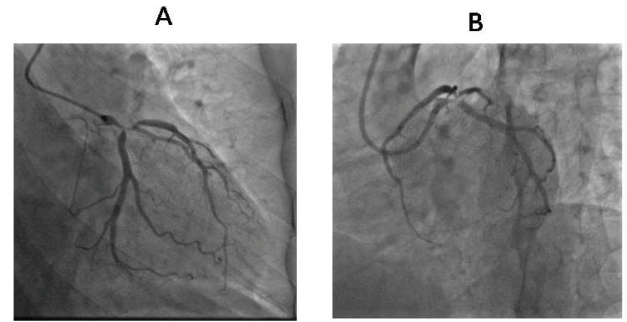


Figure 5: A & B: Baseline coronary angiography showing simple "true" left main (LM) bifurcation lesion (Medina 1,1,1).

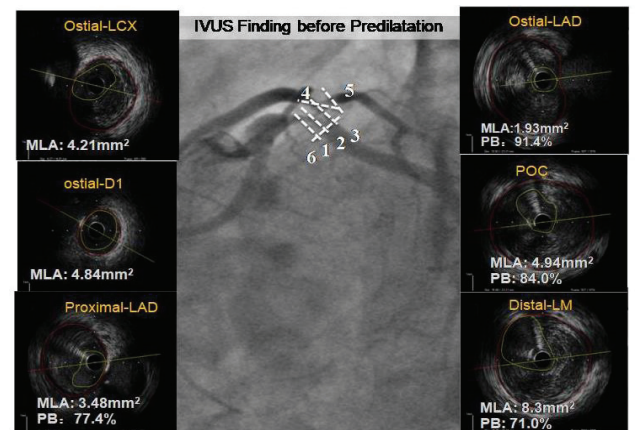


Figure 6: Intravascular ultrasound (IVUS) pullback from left anterior descending artery (LAD), first diagonal and left circumflex artery (LCX).

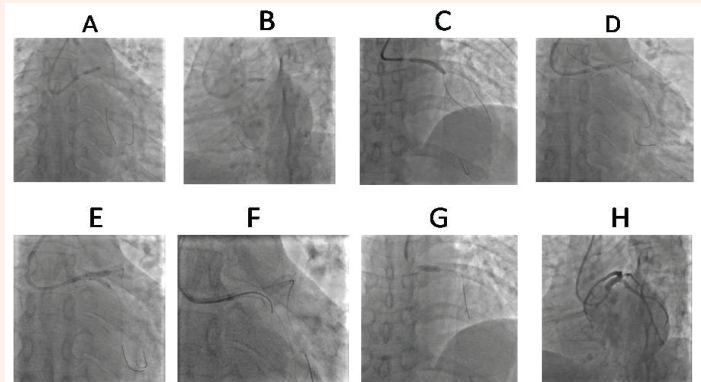


Figure 7: Step-by-step illustrations of provisional ones-stent technique.

- A. Predilatation of LAD lesion with a cutting balloon.
- B. Predilatation of LCX lesion with a cutting balloon.
- C. Stenting of the LM-LAD with jailed guidewire in LCX.
- D. The LM's provisional optimization method (POT) makes use of a longer, broader balloon.
- E. Final kissing balloon inflation using non-compliant balloon in the LAD and LCX at medium pressure.
- F. Re-POT of the LM
- G. Final result

Provisional stenting of the SB (conversion to a two-stent strategy)

T stenting: Distal rewiring and KBI are included in the provisional

technique's initial phases. In cases when the bifurcation angle is near 90 degrees, the second stent is implanted in a T-shape to ensure that all stent struts are covered by the bifurcation [62]. However, bench testing reveals that the bifurcation angle is frequently less than 90 degrees, which might result in inadequate SB ostium scaffolding or stent protrusion into the proximal MB. Restenosis may occur if the SB ostium is not well covered, and projecting struts may prevent access to the distal MB [63].

TAP stenting: The development of TAP stemmed from an understanding of its limitations. After the LM to the LAD stent has been placed, the POT is done [64]. The LCX is recrossed through the distal cell nearest to the carina, and the imprisoned guidewire is removed. An uninflated LAD balloon is left in the LAD while the LCX is inserted with little protrusion (1–2mm). Following stent insertion, high-pressure inflation is used to accomplish proper stent expansion at the LCX ostium level (the balloon inside the LAD is kept uninflated during this phase). By concurrently inflating the delivery balloons for the LCX stent and the LAD balloon, KBI can be accomplished (Figure 11). Using non-compliant balloons, some bench experiments show “sequence” high-pressure inflation, although simultaneous inflation and kissing balloon deflation are expected to happen (to keep the neo carina in a central position). TAP stenting removes the necessity for a second rewiring of the SB with this procedure.

When the MB stent has a long stretch and large overlaps between the balloons during kissing, a repeat final POT is contemplated (this can result in an oval MB result). TAP stenting removes the requirement for a second rewiring of the SB by its use. NE ocarina length is governed by SB takeoff angle and the neo carina's strut crossing point. This is a possible downside of this technology. For the ostium of the LCX to be preserved, a T-shaped takeoff is necessary with a little protrusion of the stent inside the LM. When the SB angle is more acute (Y-shaped), the Ostia are longer and oval-shaped. This means that a larger protrusion is required for the stent to enter [19]. Preference of provisional stenting vs. two stent strategy is discussed in (Table 2) (a) & 2(b). The chance of side branch compromise “Eyebrow” signs in (Figure 12). The stent deformity caused by catheter seen in IVUS and POT done to correct it is shown in (Figure 13).

Intentional two-stent techniques

Culotte stenting: When a second stent was necessary, Chevalier et al [65], first described the culotte procedure as an auxiliary to the provisional

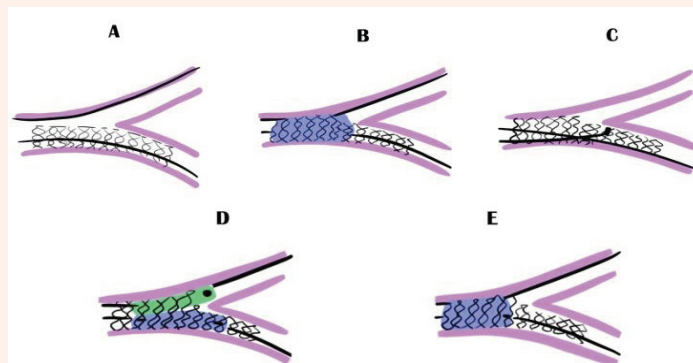


Figure 9: Schematic illustration of provisional stenting with one stent cross over.

A. Stenting of the main branch ([left main] LM) to left anterior descending artery (LAD) across the side branch (the left circumflex artery [LCX]) take-off with the stent sized 1:1 according to LAD.
 B. The proximal optimization technique (POT) with a short balloon with diameter adapted to LM diameter with the tip marker ending in front of the carina.
 C. The distal recross (closest to carina) of the side branch with the main branch guidewire or a new guidewire. The double bent guidewire tip shape that allows entering easily the distal part of the side branch ostium.
 D. Kissing balloon inflation (KBI) with 2 short, preferably non-compliant balloons sized with both distal branches with the side branch balloon minimally extending beyond the ostium.
 E. Re-POT.

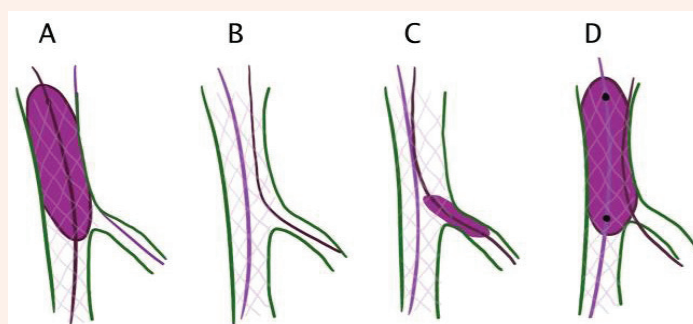


Figure 10: Illustration depicting POT side POT.

A. First POT
 B. Guidewire exchange
 C. Side branch dilatation
 D. Re-POT
 Provisional stenting of the SB (conversion to a two-stent strategy)

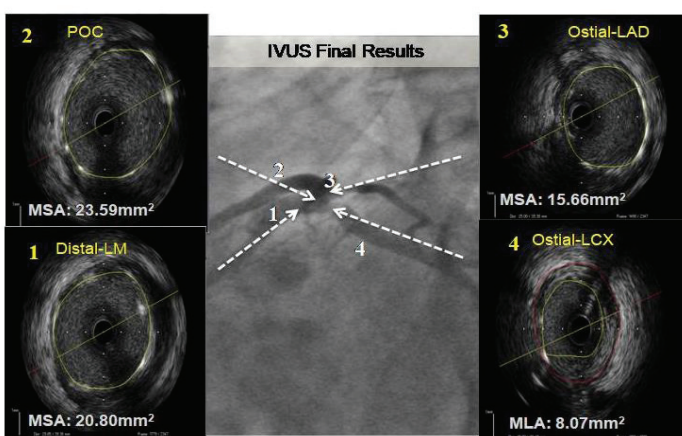


Figure 8: IVUS depiction of the final result.

approach. A temporary culotte is yet another name for this style. “Inverted culotte” is a term used to describe the procedure in which the first stent in the SB is inserted before the secondary stent is placed. The initial stent is placed into the most angulated branch, often the SB (LM-LCX), which protrudes into the proximal MB after LM-LCX predilation. The stent is long enough to allow POT in the LM and is sized according to the LCX diameter. An LM calibre stent is used to post-dilate the stent all the way to the carina (POT technique). The LCX pullback method is used to achieve distal rewiring of the LAD at the carina. High-pressure dilatation of the LM-LAD (or KBI) is used to open the struts toward the LAD.

It is then followed by the second POT in the same manner as the first POT. Through the distal cell and ultimately the final KBI, short non-compliant balloons rewire the LCX stent (consecutive high-pressure inflation followed by simultaneous KBI). The POT marks the end of the process. POT is recommended after the first and second stent deployments,

as well as a final POT after KBI in modern culotte stenting. POT (Figure 14). Proximal MB overhang should be prevented wherever possible (mini culotte). Near-perfect carina and ostium coverage is ensured with this technique. Limitations include the difficulty of wiring both branches via struts and the time required to do it. According to a bench investigation, following culotte stenting, a “napkin” or gap appears at the SB ostium, resulting in failure to completely scaffold the ostium and elevated ISR, TLR, and ST [66].

Bench testing has shown that the DK culotte technique, which entails optimizing the SB outcome with additional KBI before stenting the MB, can enhance the culotte stenting technique [67]. It capacities in order less time to complete procedures with the DK culotte while yet providing better overall end-strut placement results. This approach may be better than DK Crush and traditional culottes at this level of devotion. The clinical validity of this will have to be tested in a bigger RCT [67]. The steps of culotte technique are discussed in (Figure 15). (Table 3).

Table 2(a) - Preference to provisional stenting.

- LM to LAD stent-
 1. Small LCX
 2. No LCX disease
 3. Wide angle LCX/LAD
- LM to LCX stent-
 - LAD ostium free from disease
 - LCX with significant vessel dominant

Table 2(b) - Preferences of 2-stent Technique.

- No small LCX with any of the following-
 1. Significant and long lesion in Ostium
 2. Complex lesion in Ostial LCX
 3. Narrow angle LAD- LCX
- Poor result after Provisional stenting-
 1. Stenosis->75%
 2. Reduced Flow
 3. Dissection

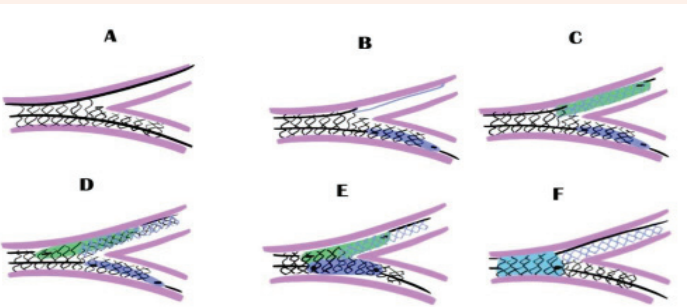


Figure 11: T stenting and minimal protrusion.
 A. The provisional stenting up to kissing balloon inflation (KBI).
 B. The positioning of the side branch stent with minimal protrusion into the left main (LM) and an uninflated balloon in the distal main branch (left anterior descending artery [LAD]).
 C. Stenting of the side branch (left circumflex artery [LCX]) with the main branch balloon uninflated.
 D. Inflating the ostium of the side branch with high pressure after pulling back the balloon below
 E. KBI after alignment of the main branch balloon and the side branch stent’s balloon.
 F. The proximal optimization technique.

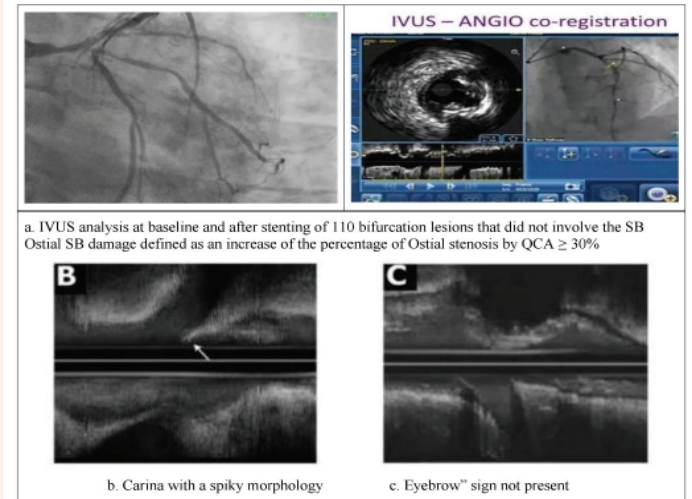


Figure 12: The risk of SB compromise- “Eyebrow” sign. IVUS analysis at baseline and after stenting of 110 bifurcation lesions that did not involve the SB Ostial SB damage defined as an increase of the percentage of Ostial stenosis by QCA $\geq 30\%$
 B. Carina with a spiky morphology
 C. “Eyebrow” sign not present

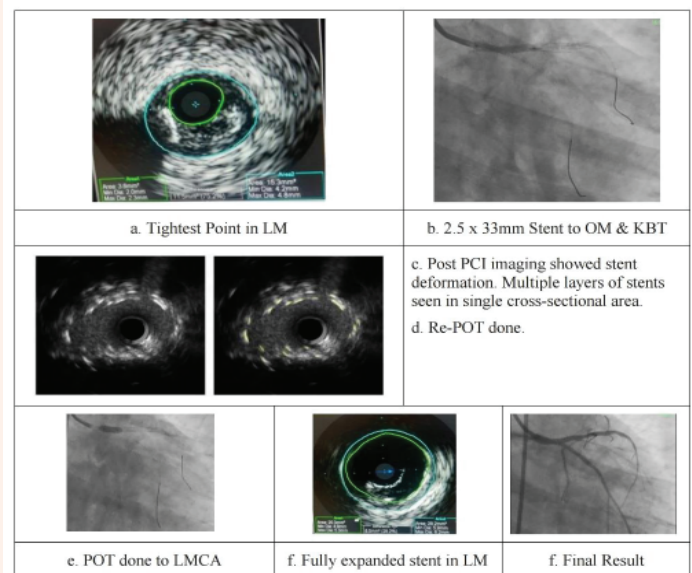


Figure 13: Stent deformation by catheter seen in IVUS and POT done.
 a. Tightest Point in LM
 b. x 33mm Stent to OM & KBT
 c. Post PCI imaging showed stent deformation. Multiple layers of stents seen in single cross-sectional area.
 d. Re-POT done.
 e. POT done to LMCA
 f. Fully expanded stent in LM
 g. Final Result

DK crush stenting

First reported on by Colombo in 2003, it is known as the crush technique [58]. After the second stent was deployed, it was discovered that the wire/balloon recrossing was not predictable. There are lower results in follow-up because the final KBI is difficult, if not impossible, soon after the standard crush procedure. Final KBI (20-25 percent after

the classic crush) is related with significant decreased rates of ST and in-stent-restenosis (ISR). According to the bench test, the stent platform, anomalous and minuscule stent cell, severe deformation of the MB stent, and anomalous overlapping of three layers of stent struts are all to blame for the failure to kiss [59]. Chen et al's DK-crush technique (Table 4) [56] utilizes the KBI twice to overcome the issues of the traditional crush technique [70].

Following LAD and LCX predilatation, a stent is positioned from the LM into the LCX (enough length to cover LCX disease and scaled 1:1 according to the LCX). The LCX stent should extend 2–3 mm into the lumen of the LM. Balloons are inserted in the LM-LAD according to the MB. It's time to place the LCX stent in place and inflate the balloon to high pressure (the balloon in the LM-LAD is kept uninflated during this phase). The key aims of this "SB optimization" technique are stent apposition and enlargement at the SB ostium [71]. Finally, the LCX guidewire and balloon are yanked out of their connection. It is necessary to use the LM-LAD balloon to compress the stent's protruding end against the LM wall prior to implantation. Reshaping the LCX and first KBI in a sequential fashion is the goal of this stent design (alternate isolated high-pressure inflations of each, followed by simultaneous KBI and deflation at the end). When all the balloons and LCX guidewires have been removed, the LM-LAD segment will be stented and then POT will be inserted. Finally, the final KBI is conducted by sequentially inserting the wire into each of the cells in the LCX (proximal to mid cell) (alternate isolated high-pressure inflations of each, followed by simultaneous KBI and deflation at the end). Because of this, the DK crush method has seven steps: Balloon-crushing of the SB stent, initial SB rewiring through the distal stent cell, first KBI, MB stenting followed by POT, final KBI and the POT after SB stenting with a 2–3 mm protrusion into MB (Figure 16).

Is DK crush going to crush other rival techniques- a field which requires further exploration.

T stenting in complicated LM bifurcation is not always ideal and

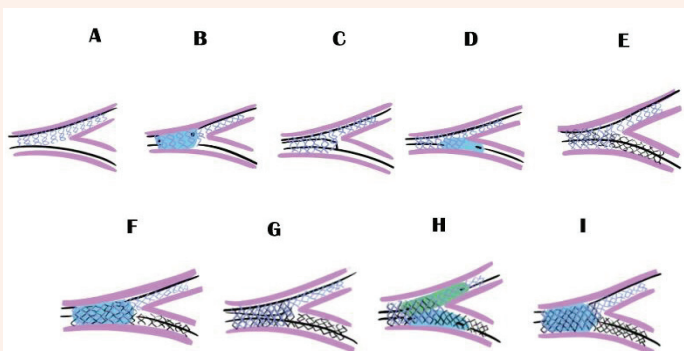


Figure 14: Culotte technique.

- A. The side branch ([left circumflex artery]) is sized 1:1 in accordance with the SB when the stent is implanted from the left main (LM). To minimise the amount of space taken up by overlapping stents, it is best to have a short LM coverage.
- B. First proximal optimization technique (POT).
- C. The distal main branch rewiring according to the pullback technique
- D. Balloon dilatation of stent struts into the main branch.
- E. The major branch from the LM to the left anterior descending artery is stented (LAD)
- F. Second POT
- G. Distal side branch rewiring closest to carina
- H. Kissing balloon inflation
- I. Final POT

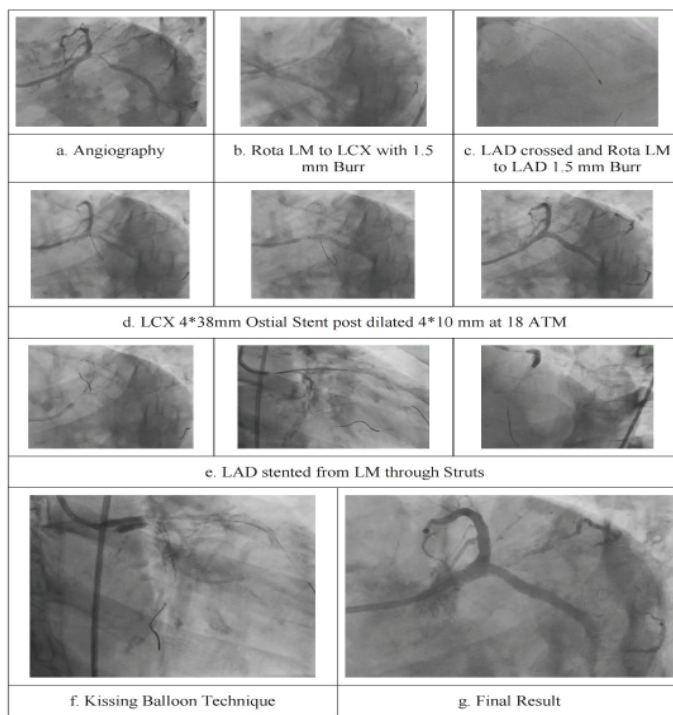


Figure 15: Calcified LM bifurcation done with Rota followed by Culotte technique.

- a. Angiography
- b. Rota LM to LCX with 1.5 mm Burr
- c. LAD crossed and Rota LM to LAD 1.5 mm Burr
- d. LCX 4*38mm Ostial Stent post dilated 4*10 mm at 18 ATM
- e. LAD stented from LM through Struts
- f. Kissing Balloon Technique
- g. Final Result

Table 3: Learning tips.

- Multilayered Provisional strategy remains the treatment of choice for Left Main Bifurcation Lesions.
- In Provisional stenting Second stent can be deployed is and when required
- There is a considerable role of IVUS Imaging and Physiology in optimizing the results and improving outcomes
- Culotte's technique can be used as a provisional stent strategy double kissing Culotte should be the preferred technique
- In Patients who present as ACS, SKS is still a viable technique. It is especially useful if Caliber of Left Main is too large and branches of LAD and LCX are disproportionately small.

predictable, implying that intentional double stenting should be utilized instead [72]. T, TAP, culotte, DK crush and V stenting procedures have been described and reviewed. These intricate procedures include several metallic layers, frequent strut malposition, neo carina development, inadequate vascular coverage, or significant stent deformation. In the MB, malposition is expedited when two or three layers of stent struts are superimposed (culotte) or crushed (crush) (Table 4) [56]. Proximal and relatively close layers of Stent Struts are potential sites for the growth of Stent thrombosis (ST) [56, 73] Many struts are juxtaposed following NE ocarina TAP and V Stenting, which may put ST at risk (Table 5) [56].

The crush technique's flaws have been addressed to a larger extent using double kissing. The SB ostium is connected to the MB by two sets of stent struts after inflation of the SB stent. Because of this, the first

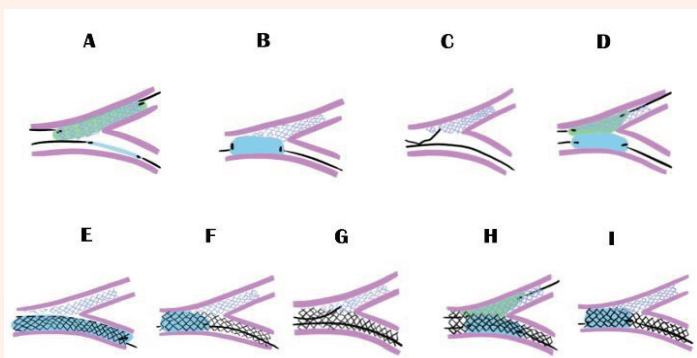


Figure 16: Double kissing crush technique.

- A. The stenting of the side branch with a 2 to 3 mm long main branch protrusion. Stent balloon inflation at a high pressure after the balloon has been deflated.
- B. Proximal main branch crushing of side branch protruding struts by an adequately sized balloon. After removing the balloon and guidewire from the side branch.
- C. Proximal side branch rewiring.
- D. The ostium of the SB is dilated with high pressure before the first kissing balloon is inflated. (KBI).
- E. After removing the guidewire from the side branch, the main branch was stented over it.
- F. First proximal optimization technique (POT).
- G. Second side branch guidewire recrossing through the proximal-mid stent cell.
- H. Consecutive deflation followed by a second KBI at 12 atmospheric pressures, followed by a 16-atm sequential inflation.
- I. Final POT.

Table 4: Merits and demerits of various two-stent techniques in left main bifurcation [56].

Techniques	Merits	Demerits
T stent	<ul style="list-style-type: none"> • Easy & not technically demanding 	<ul style="list-style-type: none"> • Potential gap in stent scaffolding & increased ostial ISR
TAP	<ul style="list-style-type: none"> • No need for 2nd SB recrossing • Minimal stent overlap • Good reconstruction of bifurcation 	<ul style="list-style-type: none"> • Risk of misplacing the SB stent • Neocarina
Culotte	<ul style="list-style-type: none"> • Near perfect SB scaffolding 	<ul style="list-style-type: none"> • Rewiring both the MB & SB through double layers of stent strut is technically demanding
V	<ul style="list-style-type: none"> • Doesn't require recrossing of the stent • Easy, fast, ideal in emergencies 	<ul style="list-style-type: none"> • Double neocarina in the MB increases the incidence of ST
Crush	<ul style="list-style-type: none"> • Near complete SB scaffolding • Ensures the patency of both the MB & SB throughout the procedure 	<ul style="list-style-type: none"> • Difficulty in rewiring the SB through triple stent layers • Final KBI (70-80%) • Kissing unsatisfactory (abluminal side branch wiring)
DK crush	<ul style="list-style-type: none"> • Complete scaffolding of the SB • Single stent layer in MB • The MB doesn't require rewiring • Final KBI (100%) • Kissing satisfactory 	<ul style="list-style-type: none"> • Suboptimal recrossing of the SB • Difficult delivery of the MB stent after first KBI

Table 5: Comparison of double kissing (DK) crush with classical crush stenting technique.

Variables	DK crush	Classical crush
Guide catheter	6F	7F
Anatomy	Suitable for all bifurcation angles	Unsuitable for wide angled bifurcation
Procedure type	Straightforward and reliable	Complex
Procedure time	Short	Longer than DK crush
Contrast use	Less	More
First kissing balloon inflation	Done	Not done
Final kissing balloon inflation	100%	70-80%
Kiss quality	Satisfactory	Unsatisfactory (abluminal side branch wiring)
Metal overlap	Less (Two layers)	More (3 layers)
Side branch ostial scaffolding	Full	Incomplete
Stent thrombosis & in-stent restenosis	Negligible	Significant

KBI may be able to correct the SB's deformed stent and leave only one layer of struts at the SB ostium, making the second KBI easier. Using DK crush over traditional crush has the additional benefit of minimizing repetitive distortion of the SB ostial stent, which allows the initial KBI to accurately replicate the bifurcation anatomic shape. Laminar flow in the MB and SB should theoretically be maximized by this method [56]. When compared to classical crush, this innovative DK crush technique has a significantly shorter procedural time, lower contrast utilization, and a higher final KBI rate (100 percent vs 70 percent; p<0.01), resulting in an improved angiographic result with residue left stenosis. According to the [74] DK-CRUSH V trial, DK-crush is superior to provisional stenting for the treatment of LM bifurcation [53] As much as 30% of patients with complicated LM bifurcation benefit most from the DK-crush procedure. In DK crush patients, the TLF rate is 5.0 percent, and in provisional stenting patients, it is 10.7 percent.

It has been shown that DK crush reduces the risk of MI in the target vessel as well as ST, clinically induced TLR, and angiographic ISR [54]. In the NOBLE and EXCEL trials, the PCI arm would have benefited much more from greater use of the DK crush approach. The DKCRUSH-III trial indicated that the DK crush approach outperformed the culotte technique in patients with a high-risk LM bifurcation [23, 24]. With a 100% retention rate, it's safe to say that this is a very high-quality study. At 1 and 3 years, the culotte group had greater MACE than the DK crush group. Bifurcation rheology is improved by DK crush. A more physiological flow is hoped to be accomplished by giving reduced metal covering on the carina side and complete metal coverage on the other side of the carina and the ostium of the SB, as shown in the illustration [75] (Table 6). The DK crush technique and its practical pitfalls are depicted in (Figure 17, 18, 19 & 20).

LM trifurcation

The LM trifurcation seen in 10% of CAG cases causes genuine technical issues. The fundamental rules of bifurcation treatment, however, can be applied to trifurcations, and provisional SB stenting is the preferred approach when feasible. The key distinction is the requirement to protect two SBs rather than one. As a result, it is recommended that a larger guide

be used, as well as two protective wires. If the SBs have limited disease, a triple KBI, also known as trussing, is associated with favorable short- and long-term outcomes. SBs of significant size and diseases may necessitate two or three stent techniques, according to categorical anatomy [19].

Post procedure IVUS and OCT

IVUS is regarded as a valuable tool in the process of selecting the best course of treatment. Utilizing IVUS-guided PCI, Park et al. found lower death rates with no difference in MI or TLR [76]. It has been shown that IVUS can significantly lower the risk of ST in complicated LM lesions after PCI [77]. IVUS-guided LM PCI decreased the incidence of a composite primary endpoint of mortality, ST, and ISR over a 5-year period, according to Andell et al [78].

The most common cause of DES failure is stent under expansion. The best predictor of ISR and early ST is MSA smaller than 5.0–5.5mm² [79, 80]. As reported by Kang SJ et al in IVUS analysis, a segmental MSA cutoff value was employed to prognosticate ISR for ostial LCX, ostial LAD, POC, and proximal LM of 5.0mm², 6.3mm², 7.2mm² and 8.2mm² respectively.




Figure 17:DK crush and practical pitfalls.

1. SB stenting with minimal protrusion towards MB
 2. SB stent with large balloon in MB
 3. SB wire recrossing at proximal-mid cell of the SB stent
 4. 1st KBT
 5. MB stenting
 6. POT
 7. SB wire recrossing at distal cell of the MB stent
 8. 2nd KBT
 9. Re-POT
- Incomplete SB stent apposition at the carina.
- a. SB stent implantation → 12 atm
 - b. Because of the curvature, SB stent could not be completely apposed to the carina.
 - c. Additional proximal dilatation → 18 atm
 - d. Because of the compliance of the balloon, with high pressure, the malapposed struts could be corrected.

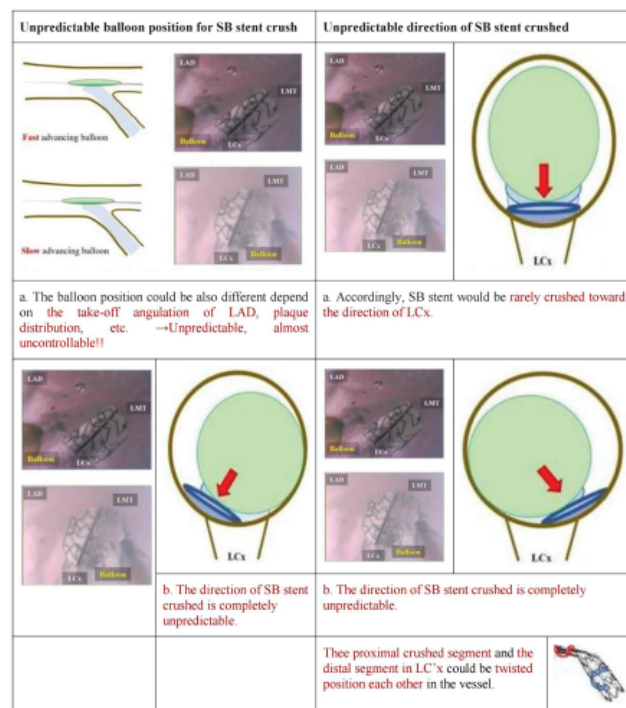


Figure 18: DK crush and practical pitfalls.

- Unpredictable balloon position for SB stent crush
- a. The balloon position could be also different depend on the take-off angulation of LAD, plaque distribution, etc. →Unpredictable, almost uncontrollable!!
 - b. The direction of SB stent crushed is completely unpredictable.
- Unpredictable direction of SB stent crushed
- a. Accordingly, SB stent would be rarely crushed toward the direction of LCx.
 - b. The direction of SB stent crushed is completely unpredictable.
- These proximal crushed segment and the distal segment in LC'x could be twisted position each other in the vessel.

Restenosis is more likely with stent under expansion in the LCX ostium and the residual metallic carina following two-stent methods in the LM, therefore IVUS-guided stent expansion is beneficial in this case.

Range of spectral frequencies More clearly than IVUS, OCT may identify malposition of the stent, edge dissections and tissue protrusions [81, 82]. The feasibility and safety of optimizing LM PCI using OCT have been demonstrated [83, 84]. OCT-guided LM bifurcation PCI is hampered by the presence of additional artefacts and the limited depth and relevance of blood clearance. Compared to 2D-OCT guidance, 3D-OCT guidance offered significantly less incomplete strut apposition after LM bifurcation stenting and KBI with guidewire recrossing point evaluation [85].

The ability to clearly see the calcium border and perform proper lesion preparation with atherectomy in calcified lesions is another benefit of employing OCT guidance. For LM lesions, IVUS guidance is often preferred over OCT guidance because of constraints in full vessel flushing and sufficient assessment of OCT guidance.

Conclusion

The bifurcation of the LM is treated as a separate entity because of the greater myocardium at risk, the broader bifurcation angle, and the near-equal importance of the MB and SB. Stenting has comparable mortality and morbidity rates to CABG, which has prompted many interventional cardiologists to use PCI with DES for LM revascularization. LM bifurcation




Figure 19: DK crush and practical pitfalls.
 a. Incomplete SB stent crush with the balloon
 b. Possibility of unfavorable SB rewiring position
 SB rewiring position: which is favorable? Far distal? or Central?




Figure 20: DK crush and practical pitfalls.
 a. Risk of SB stent deformation during SB balloon delivery
 b. Final stent results of DK crush

and trifurcation lesions continue to pose significant technical challenges, necessitating expertise and novel approaches for optimal outcomes. Because of this, an integrated strategy combining more modern devices with specialized techniques and adjunctive physiologic and imaging guidance is needed for dramatically increasing PCI success rates and long-term clinical outcomes in this complex subset.

Author Contributions

The lead author of the case report is Dr Rohit Mody. Dr Debabrata Dash, Dr Bhavya Mody had equal and substantial contributions in the formation of this case report. They were involved in conceptualization, data curation, formal analysis, resources, software, validation, visualization, writing - original draft, Writing, review & editing.

Availability of data and materials

The datasets used and/or analyzed during the current study are available from the corresponding author on reasonable request.

Ethics approval and consent to participate

Ethical approval was not required since it is an accepted procedure.

Consent for publication

Written consent has been obtained to publish the case report from the guardian. The consent copy is available with the authors and ready to be submitted if required.

Acknowledgement

I thank Ms. Nikita and Ms. Shikha Kumari for assisting me to finalize the research article. Figures are edited by Jiwan Singh.

Abbreviations

ACS- Acute Coronary Syndrome; ATM- Ataxia Telangiectasia Mutated; CABG- Coronary Artery Bypass Surgery; CAG- Coronary Angiogram; DES- Drug Eluting Stent; EBC- European Bifurcation Club; FFR- Fractional Flow Reserve; ISR- In-stent Restenosis; IVUS- Intravascular Ultrasound; KBI- Kissing Balloon Inflation; KBT- Kissing Balloon Technique; LAD- Left Anterior Descending; LAO- Left Anterior Oblique; LCX- Left Circumflex Artery; LM- Left Main; LMCAD- Left Main Coronary Artery Disease; MACE- Major Adverse Cardiovascular Events; MB- Main Branch; MI- Myocardial infarction; MLA- Minimum Lumen Area; OCT- Optical Coherence Tomography; OM- Obtuse Marginal; PCI- Percutaneous Coronary Intervention; POT- Proximal Optimization; QCA- Quantitative Coronary Angiography; RCT- Randomised Clinical Trial; SB- Side Branch; SKS- Simultaneous Kissing Stents; ST- Sinus Tachycardia; STS- Stent Struts; TAP- T and Small Protrusion; TIMI- Thrombolysis in Myocardial Infarction; TLR- Target Lesion Revascularization; TVF- Target Vessel Failure; WSS- Wall Shear Stress.

References

- DeMots H, Rösch J, McAnulty JH, Rahimtoola SH (1977) Left main coronary artery disease. *Cardiovasc Clin* 8: 201-211. Link: <https://bit.ly/3OFFa66>
- De Caterina AR, Cuculi F, Banning AP (2013) Incidence, predictors, and management of left main coronary artery stent restenosis: A comprehensive review in the era of drug-eluting stents. *Eurointervention* 8:1326-1334. Link: <https://bit.ly/318F18N>
- Taylor HA, Deumite NJ, Chaitman BR, Davis KB, Killip T, Rogers WJ (1989) Asymptomatic left main coronary artery disease in the coronary artery surgery study (CASS) registry. *Circulation* 79: 1171-1179. Link: <https://bit.ly/3nvMiX1>
- Chaitman BR, Fisher LD, Bourassa MG, Davis K, Rogers WJ, et al. (1981) Effect of coronary bypass surgery on survival patterns in subsets of patients with left main coronary artery disease. Report of the Collaborative Study in Coronary Artery Surgery (CASS). *Am J Cardiol* 48: 765-777. Link: <https://bit.ly/3ujQMDO>
- Takaro T, Peduzzi P, Detre KM, Hultgren, Murphy ML, et al. 1982) Survival in subgroups of patients with left main coronary artery disease. Veterans Administration Cooperative Study of Surgery for Coronary Arterial Occlusive Disease. *Circulation* 66: 14-22. Link: <https://bit.ly/3yLffol>
- Dash D (2013) Stenting of left main coronary artery stenosis: A to Z. *Heart Asia* 5: 18-27. Link: <https://bit.ly/3nwn62z>
- Park SJ, Park DW (2009) Percutaneous coronary intervention with stent implantation versus coronary artery bypass surgery for treatment of left main coronary artery disease: is it time to change guidelines? *Circ Cardiovasc Interv* 2: 59-68. Link: <https://bit.ly/3yzgZkk>
- Windecker S, Kolh P, Alfonso F, Jean-Philippe C, Jochen C, et al. (2014) 2014 ESC/EACTS Guidelines on myocardial revascularization: The Task Force on Myocardial Revascularization of the European Society of Cardiology (ESC) and the European Association for Cardio-Thoracic Surgery (EACTS) developed with the special contribution of the European Association of Percutaneous Cardiovascular Interventions

- (EAPCI). *Eur Heart J* 35: 2541-2619. Link: <https://bit.ly/2MZwHjK>
9. Alaide C, Seung JP, Marco V, Young HK, Joost D, *et al.* (2007) Favorable long-term outcome after drug-eluting stent implantation in nonbifurcation lesions that involve unprotected left main coronary artery: A multicenter registry. *Circulation* 116: 158-162. Link: <https://bit.ly/3yDhKnF>
10. Serruys PW, Morice MC, Kappetein AP, Antonio C, David RH, *et al.* (2009) SYNTAX Investigators. Percutaneous coronary intervention versus coronary-artery bypass grafting for severe coronary artery disease. *N Engl J Med* 360: 961-972. Link: <https://bit.ly/3yaAv5m>
11. Meier B, Gruentzig AR, King SB 3rd, Douglas JS Jr, Hollman J, *et al.* (1984) Risk of side branch occlusion during coronary angioplasty. *Am J Cardiol* 53: 10-14. Link: <https://bit.ly/3P3AyGD>
12. Morice MC, Serruys PW, Kappetein AP, Ted E Feldman, Elisabeth Stähle, *et al.* (2010) Outcomes in patients with *de novo* left main disease treated with either percutaneous coronary intervention using paclitaxel-eluting stents or coronary artery bypass graft treatment in the synergy between percutaneous coronary intervention with TAXUS and cardiac surgery (SYNTAX) trial. *Circulation* 121: 2645-2653. Link: <https://bit.ly/3OICwwD>
13. Dash D (2018) Double kissing crush in left main coronary bifurcation lesions: A crushing blow to the rival stenting techniques! *Indian Heart J*. 70: 758-761. Link: <https://bit.ly/3ulfMun>
14. Dash D, Chen SL (2015) Stenting of left main coronary artery stenosis: Data to clinical practice. *J Cardiovasc Dis Diagn* 3: 222. Link: <https://bit.ly/3nwn62z>
15. Macaya C, Alfonso F, Iñiguez A, Goicolea J, Hernandez R, *et al.* (1992) Stenting for elastic recoil during coronary angioplasty of the left main coronary artery. *Am J Cardiol* 70: 105-107. Link: <https://bit.ly/3Ic4AGa>
16. Lefèvre T, Girasis C, Lassen JF (2015) Differences between the left main and other bifurcations. *Euro Interv* 11: V106-110. Link: <https://bit.ly/3yHYbiZ>
17. Maehara M, Mintz GS, Castagna MT, Pichard AD, Satler LF, *et al.* (2001) Intravascular ultrasound assessment of the stenoses location and morphology in the left main coronary artery in relation to anatomical left main length. *Am J Cardiol* 88: 1-4. Link: <https://bit.ly/3nj3wQt>
18. Binu LS, Kumar SA (2012) Simulation of Left Main Coronary Bifurcation Lesions using 3D Computational Fluid Dynamics Model and its Comparison with 2D. London, U.K: Proceedings of the World Congress on Engineering. Link: <https://bit.ly/3ldeaZi>
19. Oviedo C, Maehara A, Mintz GS, *et al.* (2010) Intravascular ultrasound classification of plaque distribution in left main coronary artery bifurcations: Where is the plaque really located? *Circ Cardiovasc Interv* 3: 105-112. Link: <https://bit.ly/3jacoxA>
20. Dash D, Chen SL, Zhang JJ (2018) Left main stenting: What we have learnt so far? *Indian Heart J Interv* 1: 18-30. Link: <https://bit.ly/3AnX9ts>
21. Adriaenssens T, Byrne RA, Dibra A, Raisuke I, Julinda M, *et al.* Culotte stenting technique in coronary bifurcation disease: Angiographic follow-up using dedicated quantitative coronary angiographic analysis and 12-month clinical outcomes. *Eur Heart J* 29: 2868-2876. Link: <https://bit.ly/3bRtb7b>
22. Dzavik V, Kharbada R, Ivanov J, Douglas J Ing, Sanh B, *et al.* (2006) Predictors of long-term outcome after crush stenting of coronary bifurcation lesions: Importance of the bifurcation angle. *Am Heart J* 152: 762-769. Link: <https://bit.ly/3Am5NIX>
23. Song PS, Song YB, Lee JM, Joo-Yong H, Seung-Hyuk C, *et al.* (2016) Major predictors of long-term clinical outcomes after percutaneous coronary intervention for coronary bifurcation lesions with 2-stent strategy: Patient-level analysis of the Korean bifurcation pooled cohorts. *JACC Cardiovasc Interv* 9: 1879-1886. Link: <https://bit.ly/3Aq1CvW>
24. Chen SL, Xu B, Han YL, Jun-Jie Zhang, Fei Ye, *et al.* (2013) Comparison of double kissing crush versus culotte stenting for unprotected distal left main bifurcation lesions: Results from a multicenter, randomized, prospective DKCRUSH-III study. *J Am Coll Cardiol* 61: 1482-1488. Link: <https://bit.ly/3yppgPdM>
25. Chen SL, Xu B, Han YL, Imad S, Jun-Jie Z, *et al.* (2015) Clinical outcome after DK crush versus culotte stenting of distal left main bifurcation lesions: The 3-year follow-up results of the DKCRUSH-III study. *JACC Cardiovasc Interv* 8: 1335-1342. Link: <https://bit.ly/3yVtelh>
26. Kassab GS, Bhatt DL, Lefèvre T, Yves Louvard (2013) Relation of angiographic side branch calibre to myocardial mass: a proof-of-concept myocardial infarct index. *EuroIntervention* 8: 1461-1463. Link: <https://bit.ly/3As3XGE>
27. Motreff P, Rioufol G, Gilard M, Christophe C, Lemlih O, *et al.* (2010) Diffuse atherosclerotic left main coronary artery disease unmasked by fractal geometric law applied to quantitative coronary angiography: an angiographic and intravascular ultrasound study. *EuroIntervention* 5: 709-715. Link: <https://bit.ly/3yktDMb>
28. Kubo S, Kadota K, Sabbah M, Suguru O, Daiji H, *et al.* (2014) Clinical and angiographic outcomes after drug-eluting stent implantation with triple-kissing-balloon technique for left main trifurcation lesion: comparison of single-stent and multi-stent procedures. *J Invasive Cardiol* 26: 571-578. Link: <https://bit.ly/3uuMqJW>
29. Tamburino C, Capranzano P, Capodanno D, Francesco T, Giuseppe B, *et al.* (2010) Plaque distribution patterns in distal left main coronary artery to predict outcomes after stent implantation. *JACC Cardiovasc Interv* 3: 624-631. Link: <https://bit.ly/3akdsgy>
30. Lefèvre T, Girasis C, Lassen JF (2015) Differences between the left main and other bifurcations. *EuroIntervention* 11: V106-110. Link: <https://bit.ly/3OSpVqu>
31. Amemiya K, Domei T, Iwabuchi M, Shinichi S, Kenji A, *et al.* (2014) Impact of the bifurcation angle on major cardiac events after cross-over single stent strategy in unprotected left main bifurcation lesions: 3-dimensional quantitative coronary angiographic analysis. *Am J Cardiovasc Dis* 4: 168-176. Link: <https://bit.ly/3yOTynh>
32. Umeda H, Gochi T, Iwase M, Hideo I, Takeshi S, *et al.* Frequency, predictors, and outcome of stent fracture after sirolimus-eluting stent implantation. *Int J Cardiol* 133: 321-326. Link: <https://bit.ly/3OPImwg>
33. Miyazaki Y, Nomura S, Miyake T, H Kagawa, C Kitada, *et al.* (1996) High shear stress can initiate both platelet aggregation and shedding of procoagulant containing microparticles. *Blood* 88: 3456-3464. Link: <https://bit.ly/3nMfMzL>
34. Lim MJ, Kern MJ (2005) Utility of coronary physiologic hemodynamics for bifurcation, aorto-ostial, and ostial branch stenoses to guide treatment decisions. *Catheter Cardiovasc Interv* 65: 461-468. Link: <https://bit.ly/3aqfeFR>
35. Vaquerizo B, Lefèvre T, Darremont O, Zwahlen M, Morice MC, *et al.* (2009) Unprotected left main stenting in the real world: two-year outcomes of the French left main taxus registry. *Circulation*. 119: 2349-2356. Link: <https://bit.ly/3yP4iSx>
36. Mylotte D, Meftout B, Moynagh A, Beatriz V, Olivier D, *et al.* (2012) Unprotected left main stenting in the real world: five-year outcomes of the French Left Main Taxus registry. *EuroIntervention* 8: 970-981. Link: <https://bit.ly/3utq63G>
37. Généreux P, Palmerini T, Caixeta A, Gregg R, Philip G, *et al.* (2012) Quantification and impact of untreated coronary artery disease after percutaneous coronary intervention: the residual SYNTAX (Synergy Between PCI with Taxus and Cardiac Surgery) score. *J Am Coll Cardiol* 59: 2165-2174. Link: <https://bit.ly/3RfZ7Cm>
38. Campos CA, Lemos PA (2013) Residual SYNTAX score for left main

- intervention: Are we really ready to predict the future? *Catheter Cardiovasc Interv* 82: 341-342. Link: <https://bit.ly/31Bye89>
39. Malkin CJ, Ghobrial MS, Raina T, Anjan Si, Allison CM, et al. (2013) Impact of incomplete revascularization in patients undergoing PCI for unprotected left main stem stenosis. *Catheter Cardiovasc Interv* 81: 939-946. Link: <https://bit.ly/3uwDjbQ>
40. Neumann F-J, Sousa-Uva M, Ahlsson A, Fernando Alfonso, Adrian PB, et al. (2019) 2018 ESC/EACTS guidelines on myocardial revascularization. *Eur Heart J* 40: 87-165. Link: <https://bit.ly/3euKcDx>
41. EACTSJM A (2019) EACTS responds to BBC Newsnight's investigation on the EXCEL trial. EACTS 2019. Accessed December 15. Link: <https://bit.ly/30KyR1f>
42. Stone GW, Kappetein AP, Sabik JF, Stuart JP, Marie-CM, et al. (2019) Five-year outcomes after PCI or CABG for left main coronary disease. *N Engl J Med* 381: 1820-1830. Link: <https://bit.ly/30SAC6g>
43. Holm NR, Mäkikallio T, Lindsay MM, Spence MS, Erglis A, et al. (2020) Percutaneous coronary angioplasty versus coronary artery bypass grafting in the treatment of unprotected left main stenosis: updated 5-year outcomes from the randomised, non-inferiority NOBLE trial. *Lancet* 395: 191-199. Link: <https://bit.ly/31qcpci>
44. Thuijs DJFM, Kappetein AP, Serruys PW, Friedrich-WM, Marie-CM, et al. (2019) Percutaneous coronary intervention
- 45 et al. (2016) Percutaneous coronary intervention for coronary bifurcation disease: 11th Consensus document from the European bifurcation club. *Eurointervention* 12: 38-46. Link: <https://bit.ly/3PwZdE7>
46. de la Torre HJM, Hernández HF, Alfonso F, Jose R Rumoroso, Ramon Lopez-Palop, et al. (2011) Prospective application of pre-defined intravascular ultrasound criteria for assessment of intermediate left main coronary artery lesions results from the multicenter LITRO study. *J Am Coll Cardiol* 58: 351-358. Link: <https://bit.ly/3zQhMvD>
47. Park SJ, Ahn JM, Kang SJ, Sung-Han Y, Bon-Kwon K, et al. (2014) Intravascular ultrasound-derived minimal lumen area criteria for functionally significant left main coronary artery stenosis. *JACC Cardiovasc Interv* 7: 868-874. Link: <https://bit.ly/2SSAJgS>
48. versus coronary artery bypass grafting in patients with three-vessel or left main coronary artery disease: 10-year follow-up of the multicentre randomised controlled SYNTAX trial. *Lancet* 394: 1325-1334. Link: <https://bit.ly/3nRnx7A>
49. Dash D (2017) Stenting or bypass surgery: overcoming the quandary for treatment choice in left main coronary artery disease in 2017. *Therapeutic Adv. Cardiol* 1: 116-120. Link: <https://bit.ly/3IxHcDi>
50. Medina A, Suárez de Lezo J, Pan MA (2006) new classification of coronary bifurcation lesions. *Rev Esp Cardiol* 59: 183. Link: <https://bit.ly/3PiobqG>
51. Lassen JF, Holm NR, Banning A, Burzotta F, Alaide Chieffo, Suárez de Lezo J, Medina A, Martín P, José Novoa, José Suárez de Lezo, et al. (2012) Predictors of ostial side branch damage during provisional stenting of coronary bifurcation lesions not involving the side branch origin: An ultrasonographic study. *Eurointervention* 7: 1147-1154. Link: <https://bit.ly/3Px0cUP>
52. Nam CW, Hur SH, Koo BK, Joon Hyung Doh, Yun-Kyeong Cho, et al. (2011) Fractional flow reserve versus angiography in left circumflex ostial intervention after left main crossover stenting. *Korean Circ J* 41: 304-307. Link: <https://bit.ly/3zL1aFP>
53. Chen SL, Ye F, Zhang JJ, Tian Xu, Nai-Liang Tian, et al. (2015) Randomized comparison of FFR-guided and angiography-guided provisional stenting of true coronary bifurcation lesions: The DKCRUSH-VI trial (double kissing crush versus provisional stenting technique for treatment of coronary bifurcation lesions VI). *JACC Cardiovasc Interv* 8: 536-546. Link: <https://bit.ly/3yMNURt>
54. Chen SL, Sheiban I, Xu B, Nigel J, Chitrapai P, et al. (2014) Impact of the complexity of bifurcation lesions treated with drug-eluting stents: The DEFINITION study (definitions and impact of complex bifurcation lesions on clinical outcomes after percutaneous coronary intervention using drug-eluting stents). *JACC Cardiovasc Interv* 7: 1266-1276. Link: <https://bit.ly/3yT2d8g>
55. Chen X, Li X, Zhang JJ, Yaling H, Jing K, et al. (2019) DKCRUSH-V Investigators. 3-Year Outcomes of the DKCRUSH-V Trial Comparing DK Crush with Provisional Stenting for Left Main Bifurcation Lesions. *JACC Cardiovasc Interv* 12: 1927-1937. Link: <https://bit.ly/3NSV8c6>
56. Hildick-Smith D, Egred M, Banning A, Philippe B, Miroslaw F, et al. (2021) The European bifurcation club Left Main Coronary Stent study: a randomized comparison of stepwise provisional vs. systematic dual stenting strategies (EBC MAIN). *European Heart Journal* 42: 3829-3839. Link: <https://bit.ly/3gR8cBk>
57. Dash D (2020) Double kissing crush and nano crush stenting in left main coronary bifurcation lesions: besting the rival techniques! *J Indian coll cardiol* 10: 105-110. Link: <https://bit.ly/3Pez1h9>
58. Dérimay F, Finet G, Souteyrand G, Luc M, Adel A, et al. (2018) Benefit of a new provisional stenting strategy, the re-proximal optimisation technique: the rePOT clinical study. *Eurointervention* 14: e325-e332. Link: <https://bit.ly/3uzCG12>
59. Murasato Y, Iwasaki K, Yamamoto T, Takanobu Y, Yutaka H, et al. (2014) Optimal kissing balloon inflation after single-stent deployment in a coronary bifurcation model. *Eurointervention* 10: 934-941. Link: <https://bit.ly/3ylcrG4>
60. Mortier P, Hikichi Y, Foin N, Gianluca De S, Patrick S, et al. (2014) Provisional stenting of coronary bifurcations: Insights into final kissing balloon post-dilation and stent design by computational modeling. *JACC Cardiovasc Interv* 7: 325-333. Link: <https://bit.ly/3yUK5KU>
61. Gwon HC, Hahn JY, Koo BK, Young Bin S, Seung-Hyuk C, et al. (2012) Final kissing ballooning and long-term clinical outcomes in coronary bifurcation lesions treated with 1-stent technique: Results from the COBIS registry. *Heart* 98: 225-231. Link: <https://bit.ly/3Pj6Xcn>
62. Chen SL, Santoso T, Zhang JJ, Fei Ye, Ya-Wei Xu, et al. (2011) A randomized clinical study comparing double kissing crush with provisional stenting for treatment of coronary bifurcation lesions: Results from the DKCRUSH-II (double kissing crush versus provisional stenting technique for treatment of coronary bifurcation lesions) trial. *J Am Coll Cardiol* 57: 914-920. Link: <https://bit.ly/3PbVvk7e>
63. Sawaya FJ, Lefèvre T, Chevalier B, Phillipe G, Thomas H, et al. (2016) Contemporary approach to coronary bifurcation lesion treatment. *JACC Cardiovasc Interv* 9: 1861-1878. Link: <https://bit.ly/3atpPqA>
64. Burzotta F, Lassen JF, Louvard Y, Thierry L, Adrian PB, et al. (2020) European Bifurcation Club white paper on stenting techniques for patients with bifurcated coronary artery lesions. *Catheter Cardiovasc Interv* 96: 1067-1079. Link: <https://bit.ly/3AF93PU>
65. Burzotta F, Gwon HC, Hahn JY, Enrico R, Jin-Ho C, et al. (2007) Modified T-stenting with intentional protrusion of the side-branch stent within the main vessel stent to ensure ostial coverage and facilitate final kissing balloon: the T-stenting and small protrusion technique (TAP-stenting). Report of bench testing and first clinical Italian Korean two-Centre experience. *Catheter Cardiovasc Interv* 70: 75-82. Link: <https://bit.ly/3yS0pw2>
66. Chevalier B, Glatt B, Royer T, Guyon P (1998) Placement of coronary stents in bifurcation lesions by the "culotte" technique. *Am J Cardiol* 82: 943-949. Link: <https://bit.ly/3apKImm>
67. Murasato Y, Hikichi Y, Horiuchi M (2009) Examination of stent deformation and gap formation after complex stenting of left main coronary artery bifurcations using microfocus computed tomography.

J Interv Cardiol 22: 135-144. Link: <https://bit.ly/3nP99g3>

68. Toth GG, Sasi V, Franco D, Anton JP, Luigi Di S, et al. (2020) Double-kissing culotte technique for coronary bifurcation stenting. *EuroIntervention* 16: e724-e733. Link: <https://bit.ly/3uAYwks>
69. Colombo A, Stankovic G, Orlic D, Nicola C, Francesco L, et al. (2003) Modified T-stenting technique with crushing for bifurcation lesions: immediate results and 30-day outcome. *Catheter Cardiovasc Interv* 60: 145-151. Link: <https://bit.ly/3nWpfo8>
70. Ge L, Airoid F, Iakovou I, Hakim M, Domniesz T, et al. (2005) Clinical and angiographic outcome after implantation of drug-eluting stent in bifurcation lesions with the crush stent technique. *J Am Coll Cardiol* 46: 613-620. Link: <https://bit.ly/3uxZmPd>
71. Chen SL, Yei F, Zhang JJ, LIN Song, SHAN Shou-jie, et al. (2005) DK crush technique: Modified treatment of bifurcation lesions in coronary artery. *Chinese Medical J* 118: 1746-1750. Link: <https://bit.ly/303M9F6>
72. Lavarra F (2020) Proximal side optimization: a modification of the double kissing crush technique. *US Cardiology Review* 14. Link: <https://bit.ly/3nOx0l1>
73. Burzotta F, Lassen JF, Banning AP, Thierry L, David Hildick-S, et al. (2018) Percutaneous coronary intervention in left main coronary artery disease: the 13th consensus document from the European Bifurcation Club. *EuroIntervention* 14: 112-120. Link: <https://bit.ly/3PypmCv>
74. Ormiston JA, Webster MWI, Webber B, James TS, Peter NR, et al. (2008) The "crush" technique for coronary artery bifurcation stenting: Insights from micro-computed tomographic imaging of bench deployments. *JACC Cardiovasc Interv* 1: 351-357. Link: <https://bit.ly/30Yis9E>
75. Chen SL, Zhang JJ, Ye F, Song Lin, Shoujie S, et al. (2007) DK crush (double-kissing and double-crush) technique for treatment of true coronary bifurcation lesions: illustration and comparison with classic crush. *J Invasive Cardiol* 19: 189-193. Link: <https://bit.ly/3lrr0lf>
76. Rigatelli G, Zuin M, Dash D (2018) Thin and crush: The new mantra in left main stenting? *World J Journal* 10: 191-195. Link: <https://bit.ly/3RjRIBY>
77. Park S-J, Kim Y-H, Park D-W, Seung-Whan L, Won-Jang K, et al. (2009) Impact of intravascular ultrasound guidance on long-term mortality in stenting for unprotected left main coronary artery stenosis. *Circ*

Cardiovasc Interv 2: 167-177. Link: <https://bit.ly/3j4UZGH>

78. de la Torre Hernandez JM, Baz Alonso JA, Gomez Hospital JA, Fernando Alfonso M, Tamara Garcia C, et al. (2014) Clinical impact of intravascular ultrasound guidance in drug-eluting stent implantation for unprotected left main coronary disease: pooled analysis at the patient-level of 4 registries. *JACC Cardiovasc Interv* 7: 244-254. Link: <https://bit.ly/3qjawnl>
79. Andell P, Karlsson S, Mohammad MA, Matthias G, Stefan J, et al. (2017) Intravascular ultrasound guidance is associated with better outcome in patients undergoing unprotected left main coronary artery stenting compared with angiography guidance alone. *Circ Cardiovasc Interv* 10: e004813. Link: <https://bit.ly/3nQFEut>
80. Hong MK, Mintz GS, Lee CW, Duk-Woo P, Bong-Ryong C, et al. (2006) Intravascular ultrasound predictors of angiographic restenosis after sirolimus-eluting stent implantation. *Eur Heart J* 27: 1305-1310. Link: <https://bit.ly/3bZCnGv>
81. Sonoda S, Morino Y, Ako J, Mitsuyasu T, Ali H M Hassan, et al. (2004) SIRIUS Investigators. Impact of final stent dimensions on long-term results following sirolimus-eluting stent implantation: Serial intravascular ultrasound analysis from the Sirius trial. *J Am Coll Cardiol* 43: 1959-1963. Link: <https://bit.ly/3uEtWXM>
82. Kang SJ, Ahn JM, Song H, Won-Jang K, Jong-Young L, et al. (2011) Comprehensive intravascular ultrasound assessment of stent area and its impact on restenosis and adverse cardiac events in 403 patients with unprotected left main disease. *Circ Cardiovasc Interv* 4: 562-569. Link: <https://bit.ly/3NU5VTm>
83. Waksman R, Kitabata H, Prati F, Mario A, Gary SM, et al. (2013) Intravascular ultrasound versus optical coherence tomography guidance. *J Am Coll Cardiol* 62: S32-S40. Link: <https://bit.ly/3ywrSSy>
84. Burzotta F, Dato I, Trani C, Giancarlo P, Giovanni Luigi De M, et al. Frequency domain optical coherence tomography to assess non-ostial left main coronary artery. *Eurointervention* 10: e1-8. Link: <https://bit.ly/3yWbZ9K>
85. Fujino Y, Bezerra HG, Attizzani GF, Wei W, Hirosada Y, et al. (2013) Frequency-domain optical coherence tomography assessment of unprotected left main coronary artery disease—A comparison with intravascular ultrasound. *Cathet Cardiovasc Interv* 82: E173-183. Link: <https://bit.ly/3aptsh6>
86. Nagoshi R, Okamura T, Murasato Y, Tatsuhiro F, Masahiro Y, et